

Reading in Devanagari: Insights from functional neuroimaging

Nandini Chatterjee Singh, Chaitra Rao

National Brain Research Centre, NH-8, Nainwal Mode, Manesar, Gurgaon, Haryana, India

Correspondence: Dr. Nandini Chatterjee Singh, NH-8, Nainwal Mode, Manesar – 122050, Gurgaon, Haryana, India.
E-mail: nandini@nbrc.ac.in

Abstract

Objectives: The current study used functional MRI (fMRI) to obtain a comprehensive understanding of the neural network underlying visual word recognition in Hindi/Devanagari, an alphasyllabic – partly alphabetic and partly syllabic Indian writing system on which little research has hitherto been carried out. **Materials and Methods:** Sixteen (5F, 11M) neurologically healthy, native Hindi/Devanagari readers aged 21 to 50 named aloud 240 Devanagari words which were either visually *linear* – had no diacritics or consonant ligatures above or below central plane of text, e.g. फल, वाहन, or *nonlinear* – had at least one diacritic and/or ligature, e.g. फूल, किरण, and which further included 120 words each of high and low frequency. Words were presented in alternating high and low frequency blocks of 10 words each at 2s/word in a block design, with linear and nonlinear words in separate runs. Word reading accuracy was manually coded, while fMRI images were acquired on a 3T scanner with an 8-channel head-coil, using a T2*-weighted EPI sequence (TR/TE = 2s/35ms). **Results:** After ensuring high word naming accuracy (M = 97.6%, SD = 2.3), fMRI data analyses (at FDR $P < 0.005$) revealed that reading Devanagari words elicited robust activations in bilateral occipito-temporal, inferior frontal and precentral regions as well as both cerebellar hemispheres. Other common areas of activation included left inferior parietal and right superior temporal cortices. Primary differences seen between nonlinear and linear word reading networks were in the right temporal areas and cerebellum. **Conclusion:** Distinct from alphabetic scripts, which are linear in their spatial organization, and recruit a primarily left-lateralized network for word reading, our results revealed a bilateral reading network for Devanagari. We attribute the additional activations in Devanagari to increased visual processing demands arising from the complex visuospatial arrangement of symbols in this ancient script.

Key words: Alphasyllabary; Devanagari; functional magnetic resonance imaging; reading

Introduction

Reading is acquired through formal instruction, and the neural network for reading is thought to develop by adapting already existing visual, auditory and language networks to serve a novel cognitive function.^[1] According to the neuronal recycling hypothesis proposed by Dehaene and Cohen, such adaptation of existing cortical mechanisms to new functions does not override the previous principles of organization; instead, the newly developed specialization

is heavily influenced by older cortical capacities and constraints. It is this influence that shapes culture-specific cortical differences between various writing systems.

Writing systems of the world may broadly be classified as alphabetic (English), syllabic (Japanese Kana), and logographic (Chinese).^[2] The principles of a writing system reflect fundamental writing–language relationships which vary widely on the dimensions of level of representation/grain size, transparency, and spatial layout. Therefore, a basic question of investigation has been, “Does a unified processing system for different writing systems exist, or are there differences?” In an alphabetic writing system like English or German, a grapheme is mapped to a phoneme, whereas in a syllabic writing system like Japanese Kana, a grapheme is mapped to a spoken syllable.^[3] The logographic system used in Chinese is completely different in that it maps a logographic character to a meaningful unit (a morpheme or word) that is also a spoken syllable.^[3] Despite

Access this article online

Quick Response Code:



Website:
www.ijri.org

DOI:
10.4103/0971-3026.130691

these differences, a host of studies on word recognition in Chinese,^[4] English,^[5] and Japanese Kana^[6] have shown the activation of a common cortical network, primarily in the left hemisphere, for all writing systems. Three general regions emerge as highly convergent across all writing systems, namely, the left superior posterior superior temporal gyrus (BA21/22), the left inferior frontal gyrus (BA6), and the left occipitotemporal region and mid-fusiform gyrus (BA19/37) which has also been termed the *visual word form area*.^[3,7]

However, extensive research on reading in these different writing systems has also identified specific cortical areas consistently associated with reading in a specific writing system. Reading in an alphabetic writing system, for instance, shows the involvement of the temporo-parietal region (BA21/39),^[5] while reading in Chinese invokes activation in the middle frontal gyrus (BA9/46).^[8] Studies on syllabic writing systems have been limited, but consistently report activation in the inferior parietal lobule (BA40).^[6] Additionally, these studies have also shown that for visually complex scripts like Chinese,^[9] Korean,^[10] and Japanese Kana,^[11] there is increased bilateral involvement wherein activation of right hemisphere regions including the right homolog of the visual word form area (BA37), parietal cortex (BA7), as well as right superior and middle frontal gyri (BA9/8) has been attributed to the processing of complex visuospatial information.

In this paper, we discuss Devanagari, which is an alphasyllabary. An alphasyllabary has features of both the alphabetic and the syllabic writing systems. Like alphabetic systems, alphasyllabaries distinguish vowels and consonants, and like syllabic systems, the grapheme is mapped to a syllable.^[12] The Devanagari script used to write Hindi is an alphasyllabary and a descendent of the Brahmi script. While Hindi is used by over 200 million people in South Asia,^[13] the Devanagari script is used to write several languages in North India, including Hindi, Sanskrit, Marathi, Nepali, and Konkani.

In Devanagari, the basic unit of writing is called *akshara*, which is alphasyllabic because it represents approximately one spoken *syllable* containing two *phonemes* (sounds) – one consonant and one vowel, that is, CV^[12]; in contrast, letters or graphemes in English represent single phonemes. Basic CV aksharas contain the inherent vowel sound /ʌ/ or schwa. For example, the aksharas म and ल represent /mʌ/ and /lʌ/, respectively. Other aksharas represent CV combinations like /ma:/, /mI/, and /mu:/, in which the basic consonant akshara is written with a vowel *diacritic* or symbol placed to the right, left, top, or bottom, as seen in मा, मि, and मू. Thus, both consonant and vowel parts of an akshara may be easily identified, but vowel symbols except ा (representing /a:/) are placed *nonlinearly* above or below the central line or plane of text. An additional nonlinear feature of Devanagari

is the use of consonant *ligatures* or secondary symbols added to basic aksharas, in order to represent strings or clusters of consonants as in /ldʌ/ (ल + द = ल्द), /mpʌ/ (म् + प = म्प), and /rkʌ/ (र + क = र्क).

Thus, a Devanagari word like माल (pronounced /ma: l/, meaning <goods>) is *visuospatially simple* and similar to English words because its CVC phoneme structure is represented in a linear order (e.g., /m/ followed by /a:/ followed by /l/). However, the words मील, मेल, मिल, मूल (/mi:l/, /mell/, /mIl/, and /mu: l/, meaning <mile>, <fusion>, <meet>, and <root>, respectively), as well as हल्दी (/hʌldi:/ meaning <turmeric>) and सम्पर्क (/sʌmpʌrk/ meaning <contact>) are *visuospatially complex*, unlike English words. Devanagari, therefore, consists of visuospatially simple (linear) as well as visuospatially complex (nonlinear) words.

Studies of native Devanagari readers have suggested that the visuospatial layout of written words plays an important role in shaping the cognitive mechanisms underlying reading.^[14-16] In their study, Vaid and Gupta^[16] recorded reaction time and accuracy while children as well as adults identified different types of Devanagari words. They found that participants took significantly longer and were more error-prone while reading words with the short vowel /I/ or *chhoti 'i' ki maatraa*, which violates the typical left-to-right spatial order of representing sounds in Devanagari spelling; thus, words like तिलक (/tIlʌk/) and मस्जिद (/mʌzʌdʒɪd/) elicited longer reaction times and more errors compared to control words like ईनाम (/i:na:m/) and कुर्सी (/kursi:/). Other studies have shown that errors in identifying nonlinear vowel diacritics and consonant ligatures account for the majority of mistakes made by dyslexic readers of Devanagari.^[14,15]

Cortical representations of Devanagari studied using functional neuroimaging have used both phrase and word level reading tasks. A study on silent reading of short phrases that comprised linear and nonlinear words in Devanagari by Das *et al.*,^[17] revealed cortical activations in left fusiform gyrus, inferior frontal gyrus, and bilateral insula, the brain areas typically reported while reading alphabetic scripts like English.^[18] Activation in right inferior and superior parietal lobules was also observed and attributed to the syllabic features of Devanagari, whereas bilateral activations in the middle frontal gyrus were attributed to the nonlinearity of Devanagari. Covert reading of phrases in Devanagari by Hindi–English bilinguals,^[19] also revealed a bilateral reading network, including bilateral occipital, insular, and cerebellar activation, as well as right temporal, superior parietal, and caudate clusters. The right caudate and superior parietal activation was attributed to complex visual processing necessary to cope with the nonlinearity of Devanagari.^[20] Both studies used phrase reading, which in itself is a complex process; the right hemisphere might be engaged not only during the processing of nonlinearity of Devanagari, but also by the act of reading phrases.

Studies of Devanagari word recognition have revealed activation in a network of brain regions that correspond closely to regions previously identified in studies of alphabetic as well as non-alphabetic languages, including bilateral occipital cortex and left fusiform gyrus, bilateral superior and middle temporal gyri, left inferior frontal and precentral gyri and supplementary motor area (SMA), left middle frontal gyrus, left superior and inferior parietal lobules and supramarginal gyrus, as well as bilateral cerebellum.^[21,22] Das *et al.*,^[21,22] attributed the differences between the activation observed for Devanagari and the universal reading network to the unique characteristics of Devanagari script. Thus, activation of right superior temporal as well as left inferior parietal regions in their studies was thought to be due to the phonological processing of syllable-level features of Devanagari script. Likewise, they attributed activity in the left middle frontal and superior parietal cortex to the visually complex nature of Devanagari.

However, the conclusions of the previous neuroimaging studies of Devanagari are limited by certain factors. A major consideration in the above studies is the small number of readers with homogeneous language profiles – Das *et al.*,^[21] tested 10 fluent readers, while Das *et al.*,^[22] compared three small groups of monolingual, simultaneous bilingual, and sequential bilingual readers. Therefore, the differences in neural activation patterns across studies and groups of readers might arise from differences in age of language acquisition as well as reading proficiency. Further, as a result of smaller groups, these studies were unable to statistically correct the functional magnetic resonance imaging (fMRI) activations for multiple comparisons, thereby weakening the generalizability of the results. Most importantly, both studies of word reading used only visually simple or linear Devanagari words, and hence, the results represent brain activity while reading only a sub-sample of typical Hindi/Devanagari text.^[21,22]

The present study was, therefore, aimed at providing a more comprehensive understanding of word recognition in the alphasyllabic Devanagari script, which combines a partly alphabetic and partly syllabic written representation with a complex visuospatial layout. A study of overt word reading was designed to identify the neural mechanisms underlying the decoding of visuospatial complexity in Devanagari. The task design enabled us to isolate the processing of visually complex or nonlinear features of Devanagari from those involved in processing visually simple or linear features.

Materials and Methods

Participants

Sixteen right-handed Devanagari readers (five females), aged 21 to 50, with no history of neurological disorders participated in this study. All participants had

received a minimum of 7 years of formal education in Devanagari ($M = 13.3$, $SD = 2.6$), and rated themselves as highly proficient readers of Devanagari, with an average rating of 4.8 ($SD = 0.4$) on a 5-point scale. Inclusion criteria were that participants (a) should be native readers of Devanagari whose primary literacy instruction had been in Devanagari and (b) who also reported reading Devanagari regularly during the past year (average weekly Devanagari reading of 4.9 h). Informed consent was obtained from all participants in accordance with the guidelines of the human ethics committee of the National Brain Research Centre.

fMRI experiment design

Our study involved a word reading task. Participants read aloud¹ 240 Devanagari words presented at 2s/word in 20s blocks of 10 words each, with successive blocks separated by 20s rest blocks, during which they looked passively at a fixation cursor (+) in the center of the screen. The scan sequence was approximately 16 min in duration. Stimuli included 120 linear words, that is, words with no consonant clusters or vowel diacritics (*maatras*) above or below the central plane of text (e.g. रत), as well as 120 nonlinear words, which had at least one vowel diacritic above or below the central plane and/or a consonant ligature (e.g. रेत). Efforts were made to match the phonemic length as well as syllabic complexity of linear (फल, वाहन) and nonlinear words (फल, किरण), and an equal number of words of high as well as low frequency (as subjectively judged by four researchers) was included in each group, linear and nonlinear. No word was repeated, and all stimuli were concrete nouns. Words were presented in four runs of 12 blocks each, with separate runs for linear and nonlinear words. Stimuli were presented via IFIS software (Invivo Corporation Ltd., Gainesville, Florida, USA) compatible with E-Prime v. 1.1 (Psychology Software Tools Ltd., 2001).

Image acquisition

Scanning was conducted on a 3T Philips MRI scanner equipped with an 8-channel Achieva head coil and using an echo planar imaging (EPI) sequence. Stimuli were presented on a screen outside the scanner, and retro-projected onto a mirror assembly visible to participants inside the scanner. Participants lay supine with their heads restrained by a soft strap, and were instructed to read each word aloud but with minimal movement. High-resolution structural T1-weighted images covering the whole brain were acquired from all participants for anatomical localization ($TR/TE = 8.4$ ms/3.7 ms). Functional images were acquired using a T2*-weighted echo-planar sequence of 30 axial slices parallel to the Anterior Commissure – Posterior

1 Overt reading was used in preference to silent (covert) reading because of the need to monitor participants' comfort level, attention to task, as well as accuracy of word identification. Due to participants' widely varying knowledge of and exposure to the MRI scanner, it was felt to be important to obtain an empirical index of participants' word reading performance within the scanner.

Commissure (AC-PC) plane. [TR/TE = 2 s/35 ms, flip angle 90°, field of view (FOV) = 230 mm with 64 × 64 image matrix, yielding an in-plane resolution of 3.59 × 3.59 mm). Slice thickness was 5 mm with 1 mm gap].

fMRI analysis

The imaging data were analyzed using SPM5 (Statistical Parametric Mapping, Wellcome Department of Cognitive Neurology, London, UK). The functional images were reoriented to set the origin near the intersection of the coronal plane through AC and the AC-PC line and then motion correction was performed with respect to the first functional image in each session. Anatomical image for each participant was co-registered with the first functional image and then normalized to the T1 template from the International Consortium for Brain Mapping (ICBM) project. The resulting parameters were used for normalizing^[23] all the functional images into Montreal Neurological Institute (MNI) space. Spatial smoothing with a Gaussian kernel of 8 mm full width half maximum (FWHM) and temporal filtering (Gaussian low-pass filter with 8 mm FWHM) was applied to the normalized images. The preprocessed data were analyzed using the general linear model framework.^[24] For each participant, the experimental settings (reading task vs. fixation) were modeled using boxcar functions convolved with the canonical hemodynamic response function. In addition, six regressors (right, forward, up, pitch, roll, and yaw) related to movement correction were used in the statistical model to account for any spurious activity related to head movements. The resulting maps from each subject were taken into a second-level analysis.

Group analysis was performed using the random effects approach^[25] as implemented in the SPM5 software. Contrast images computed from the subject-specific models were entered into a one-sample *t*-test at the second level. The voxel coordinates reported in Table 1 are MNI coordinates. Locations of peak activations along with their spatial extent are reported in Table 1 for various regions. Statistical thresholding at a significance level of $P < 0.005$ with false discovery rate (FDR) correction for multiple comparisons, as well as a cluster correction of $k > 10$ was applied for determining significant neural activity at the group level.

Results

Participants' word reading responses within the scanner were recorded and later analyzed manually for accuracy. As expected, participants were highly accurate at identifying individually presented words in Devanagari (mean accuracy = 97.6%, SD = 2.3).

Neuroimaging data from each participant were analyzed individually using the preprocessing steps outlined above, before being combined in a group analysis (with

Table 1: MNI coordinates of significant activations for word reading in Hindi, at FDR $P < 0.005$, $k > 10$

Brain area	BA	MNI coordinates (x y z)	Cluster size	z
Frontal				
L_precentral gy. ¹	6	-46 -4 30	443	5.64
L_IFG, pars op.	44	-52 10 16		4.13
R_precentral gy.	4	52 -2 28	618	5.52
R_IFG, pars op.	48	38 -4 26		4.58
Parietal				
R_postcentral gy.	48	62 2 16		4.70
L IPL	40	-32 -52 52	22	4.03
Temporal				
R_STG	21	48 -28 0	49	3.98
R_STP	38	52 16 -14	23	3.92
Occipital				
L_MOG	19	-36 -88 -2	1187 ²	5.57
R_IOG	19	30 -86 -4	349	5.28
R_calcarine sul.	18	18 -94 -6		5.14
R_IOG	37	40 -60 -14	560 ³	4.87
Sub-cortical				
L_insula	48	-44 6 -10	14	3.78
L_(globus) pallidum		-16 -6 -6	47	4.22
R_(globus) pallidum		18 -4 0	44	4.05
R_thalamus		24 -30 10	48	4.32
L_hippocampus		-24 -26 -8	11	3.79
L_cerebellum VI ²		-14 -60 -22		5.57
L_cerebellum VI ²		-22 -64 -24		5.57
R_cerebellum VI ³		16 -60 -24		5.36
R_cerebellum VI ³		34 -64 -24		5.13
R_cerebellum VIII		12 -72 -42	355 ⁴	6.33
R_cerebellum VIII ⁴		28 -68 -50		5.47

¹L: Left, Gy.: Gyrus, IFG: Inferior frontal gyrus, Op.: Opercularis, R: Right, IPL: Inferior parietal lobule, STG: Superior temporal gyrus, STP: Superior temporal pole, MOG: Middle occipital gyrus, IOG: Inferior occipital gyrus, Sul.: Sulcus. ^{2,3,4}Areas within a single cluster of activation share the same superscript, which follows the cluster size value at the first occurrence, and the area name in subsequent occurrences in the table

an activation threshold correction of FDR $P < 0.005$), in which separate contrasts were generated for brain activation while reading linear words, nonlinear words, as well as the cumulative neural network underlying word reading in Devanagari, all compared against the baseline or rest block activity of the brain. The results of these analyses are summarized in Figure 1. Similar to the other alphabetic writing systems,^[3] reading words written in Devanagari led to cortical activations in bilateral occipital cortex (BA18/19), bilateral precentral gyri (BA6/4), opercular region of the left inferior frontal gyrus as well as insula (BA44/48), right postcentral gyrus (BA48), and sub-cortical bilateral activation of the thalamus and bilateral cerebellum (Crus VI and VIII). In addition to these activations, identifying words in Devanagari produced activity in the left inferior parietal lobule (BA40), right superior temporal gyrus (BA21), right superior temporal pole (BA38), and right rolandic operculum of the inferior frontal gyrus (BA48), as well as sub-cortical clusters in the

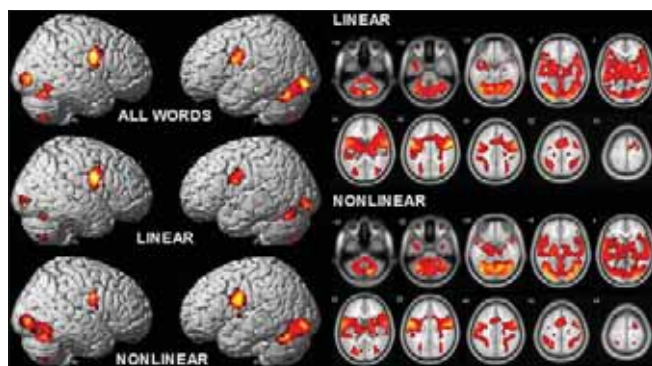


Figure 1: Sagittal 3D view of brain regions activated during visual word recognition in Hindi/Devanagari (left panel), showing cumulative activation and activation specific to visually simple linear words (रेत) and visually complex nonlinear words (रेत), rendered at FDR $P < 0.001$. Axial 2D view of activation patterns for linear and nonlinear Devanagari words (right panel)

bilateral pallidum (BA48) and left hippocampus (BA20), in alignment with the previous findings on phrase and word reading in Devanagari^[17,19,21,22] [Figure 1].

Further analyses were carried out to determine whether there was additional recruitment of brain regions while reading either type of stimuli, linear or nonlinear words. To identify such regions, two subtraction analyses were computed of group level data, in which the activation for reading nonlinear words was subtracted from that of linear words (i.e. linear minus nonlinear) and, conversely, linear activation was subtracted from nonlinear (nonlinear minus linear). When examined at a threshold of $P < 0.001$ with a cluster correction of $k > 20$ voxels, these analyses showed that reading only linear words did not produce greater brain activation. However, reading nonlinear words showed increased activity compared to linear words in the middle and inferior temporal gyri (BA21/37) as well as cerebellar Crus VI, VIIb, and VIII of the right hemisphere. Refer to Figure 2 for results of the subtraction analyses [Figure 2].

Discussion

The current study investigated the neural network involved in reading the alphasyllabary of Hindi/Devanagari, with a particular focus on the processing of visuospatial complexity. Results of an fMRI experiment on overt word naming by proficient native readers showed that the group-level brain activation pattern (corrected to FDR $P < 0.005$) resembled the universal neural network for visual word recognition,^[3] including bilateral posterior occipito-temporal cortices, left precentral and inferior frontal gyri, left insula, and bilateral cerebellum.² Importantly, the present findings corroborated the results of previous neuroimaging studies of Devanagari, revealing a highly similar pattern of neural activation to

2 Note that activations in the right precentral (BA6/4) and postcentral gyri (BA48) are associated with sensorimotor processing related to lips and tongue,^[26-28] and are therefore not discussed in detail here.

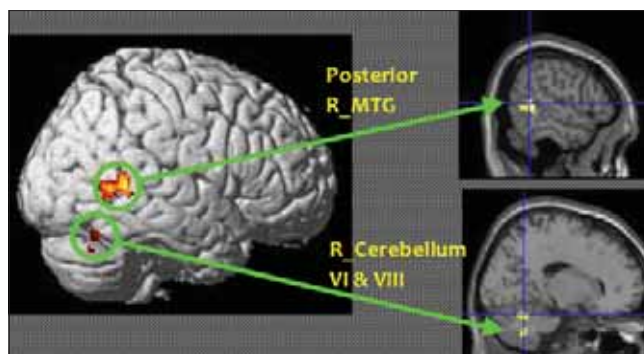


Figure 2: Subtraction analysis (at $P < 0.001$, $k > 20$) showing brain regions additionally activated while reading nonlinear words (e.g. रेत) in Hindi/Devanagari, including right middle temporal gyrus (R_MTG) at MNI 54 -48 8 ($k = 156$), right cerebellum VI at 18 -58 -24 ($k = 134$), and right cerebellum VIII at 18 -60 -42 ($k = 80$)

those obtained in Das *et al.*'s^[21,22] studies of single word reading, as well as comparable levels of similarity to earlier findings on phrase reading in Devanagari.^[17,19]

At the same time, the current study revealed differences between the universal reading network and the activation for Devanagari, attributable to the partly alphabetic and partly syllabic structure of its script, as well as to its complex visuospatial layout. The neural hallmarks of reading Hindi/Devanagari are interpreted as follows.

Previous studies of alphabetic languages have associated the processing of written word forms, that is, the visual configuration of words, with the occipito-temporal cortex of the left hemisphere.^[3,5,7,18,29] In contrast, research on visually complex, non-alphabetic scripts like Chinese, Japanese Kana and Kanji, and Korean Hangul and Hanja has documented bilateral occipito-temporal activation during word recognition.^[3,4,6,10,11,30,31] An interesting feature of the current results is the extensive bilateral occipito-temporal activation exhibited by Devanagari readers. Specifically, the visuospatially complex nonlinear words (e.g. फूल, रेत) used in this study elicited greater activity in the right occipito-temporal cortex compared to visually simple linear words (फल, रेत), with a cluster of 1529 voxels for nonlinear as compared to 137 voxels for linear words (compared at FDR $P < 0.001$). Although this difference did not manifest itself in the 'nonlinear minus linear' subtraction results, we speculate that the visuospatial complexity of Devanagari orthography is responsible for the greater involvement of right occipito-temporal cortex during reading. Further experiments with more carefully controlled stimuli, where linear and nonlinear words are matched on various features including syllable structure, phonemic length, word frequency, and bigram frequency may help in verifying a right hemispheric bias in processing visuospatially complex features of Devanagari.

With respect to the partly alphabetic and partly syllabic level of phonological information represented by Devanagari

script, the current results accordingly represent a combination of brain regions previously reported in studies of alphabetic and syllabic scripts. Thus, Devanagari readers activated regions universally associated with phonological processing,^[3,4,18,29,31] such as the pars opercularis of the left inferior frontal gyrus (BA44) as well as insular cortex (BA48) and the left precentral gyrus (BA6). At the same time, reading in Devanagari elicited robust activation of the left inferior parietal lobule (BA40), strongly linked to phonological processing of syllabic characters such as Japanese Kana.^[3,6,11]

A crucial difference between previous findings on alphabets and the current Devanagari results was the finding of significant activation in the temporal cortex of the right hemisphere, including right superior temporal gyrus (BA21) and right temporal pole (BA38). Past research has implicated the right superior temporal region in extracting phonological information from the visuospatially complex Chinese script, in which, moreover, each character represents approximately one spoken syllable.^[31,32] Das *et al.*'s studies of word as well as phrase reading in Devanagari have consistently observed activation of the right superior temporal gyrus,^[17,21,22] and Kumar *et al.*,^[19] additionally documented right superior temporal pole activation. In the current study, we therefore attribute our finding of right superior temporal activation in reading Devanagari to the need for extracting phonological information from a complex visuospatial configuration, in which both syllable and phoneme level information is represented. This interpretation is supported by our finding of increased right temporal activation by visually complex, that is, nonlinear compared to simple or linear words [Figure 2].

An additional feature of interest in the results of the present study is the extensive cerebellar activation observed in this study, including bilateral activation of Crus VI and VIII. An anonymous reviewer raised the concern that this pattern might arise from the use of an overt reading task in which motor coordination and control, rather than reading-related cognitive processes might be responsible for cerebellar activation. Although this possibility cannot be ruled out on the basis of the current results alone, the right cerebellum Crus VI and VIII have previously been implicated in coordinating phonological processing as well as verbal working memory with higher cortical centers.^[33,34] Further, a study previously published by our laboratory revealed robust cerebellar activation during a silent word recognition task in Hindi/Devanagari.^[35] And finally, the finding in the present study that nonlinear words elicited greater cerebellar activation compared to linear words ('nonlinear minus linear' subtraction) suggests that the role of the cerebellum is not limited merely to initiating or facilitating motor output during Devanagari word recognition.

In summary, the current article highlights the universal nature of the neural network underlying word recognition, while bringing to attention some of the unique features associated with reading in an alphasyllabic script such as Hindi/Devanagari. The present findings tally well with the results of previous studies of reading in Hindi/Devanagari.^[17,19,21,22] Our results indicate that the visuospatial complexity of Devanagari script as well as its partly alphabetic and partly syllabic phonological representation might impose unique cognitive demands on the underlying brain mechanisms, resulting in activation of brain regions such as the right occipito-temporal cortex (BA19/37), left inferior parietal lobule (BA40), and right temporal cortex (BA21/22). Areas activated by Devanagari have previously been associated with the processing of alphabetic as well as syllabic scripts, and specifically with the decoding of visuospatially complex scripts like Chinese and Japanese. A further characteristic of Devanagari is the strong and extended bilateral cerebellar activation, which we attribute to the cognitive demand upon phonological working memory imposed by this visuospatially complex script. The results presented here are preliminary, however, and further work is needed in order to corroborate and extend the present findings.

References

1. Dehaene S, Cohen L. Cultural recycling of cortical maps. *Neuron* 2007;56:384-98.
2. Perfetti CA, Liu Y. Orthography to phonology and meaning: Comparisons across and within writing systems. *Read Writ* 2005;18:193-210.
3. Bolger DJ, Perfetti CA, Schneider W. Cross-cultural effect on the brain revisited: Universal structures plus writing system variation. *Hum Brain Mapp* 2005;25:92-104.
4. Tan LH, Laird A, Li K, Fox PT. Neuroanatomical correlates of phonological processing of Chinese characters and alphabetic words: A meta-analysis. *Hum Brain Mapp* 2005;25:83-91.
5. Moore CJ, Price CJ. Three distinct ventral occipitotemporal regions for reading and object naming. *Neuroimage* 1999;10:181-92.
6. Ino T, Nakai R, Azuma T, Kimura T, Fukuyama H. Recognition and reading aloud of Kana and Kanji words: An fMRI study. *Brain Res Bull* 2009;78:232-9.
7. McCandliss BD, Cohen L, Dehaene S. The visual word form area: expertise for reading in the fusiform gyrus. *Trends Cogn Sci* 2003;7:293-9.
8. Tan LH, Spinks JA, Feng CM, Siok WT, Perfetti CA, Xiong J, *et al.* Neural systems of second language reading are shaped by native language. *Hum Brain Mapp* 2003;18:158-66.
9. Perfetti CA, Liu Y, Fiez J, Nelson J, Bolger DJ. Reading in two writing systems: Accommodation and assimilation of the brain's reading network. *Biling (Camb Engl)* 2007;10:131-46.
10. Yoon HW, Cho K, Chung J, Park HW. Neural mechanisms of Korean word reading: A functional magnetic resonance imaging study. *Neurosci Lett* 2005;373:206-11.
11. Nakamura K, Dehaene S, Jobert A, Bihan DL, Kouider S. Subliminal convergence of Kanji and Kana words: Further evidence for functional parcellation of the posterior temporal cortex in visual word perception. *J Cogn Neurosci* 2005;17:954-68.
12. Bright W. A matter of typology: Alphasyllabaries and abugidas. *Stud Linguist Sci* 2000;30:63-71.

13. Paul LM, Simons GF, Fennig CD, editors. *Ethnologue: Languages of the World*. 17th ed. Dallas, USA: SIL International. Retrieved from: <http://www.ethnologue.com>.
14. Gupta A, Vaid J, Garg A. Word–nonword reading in Hindi language by developmentally dyslexic children. Poster presented at the 38th annual meeting of the Psychonomic Society, Philadelphia: USA; November 1997.
15. Nehru R, Garg A. A cross-linguistic study of biliterate developmental dyslexia. Paper presented at the 5th annual conference of the Indian Academy of Neurology, Madras: India; September 1997.
16. Vaid J, Gupta A. Exploring word recognition in a semi-alphabetic script: The case of Devanagari. *Brain Lang* 2002;81:679-90.
17. Das T, Kumar U, Bapi RS, Padakannaya P, Singh NC. Neural representation of an alphasyllabary- The story of Devanagari. *Curr Sci* 2009;97:1033-8.
18. Price CJ. The anatomy of language: Contributions from functional neuroimaging. *J Anat* 2000;197:335-59.
19. Kumar U, Das T, Bapi RS, Padakannaya P, Joshi RM, Singh NC. Reading different orthographies: An fMRI study of phrase reading in Hindi-English bilinguals. *Read Writ* 2009.
20. Poldrack RA, Desmond JA, Glover GH, Gabrieli JD. The neural basis of visual skill learning: An fMRI study of mirror reading. *Cereb Cortex* 1998;8:1-10.
21. Das T, Bapi RS, Padakannaya P, Singh NC. Cortical network for reading linear words in an alphasyllabary. *Read Writ* 2011a; 24:697-707.
22. Das T, Padakannaya P, Pugh KR, Singh NC. Neuroimaging reveals dual routes to reading in simultaneous proficient readers of two orthographies. *Neuroimage* 2011b; 54:1476-87.
23. Friston KJ, Frith CD, Frackowiak RS, Turner R. Characterizing dynamic brain responses with fMRI: A multivariate approach. *Neuroimage* 1995;2:166-72.
24. Friston KJ, Holmes AP, Worsley KJ, Poline JB, Frith CD, Frackowiak RS. Statistical parametric maps in functional imaging: A general linear approach. *Hum Brain Mapp* 1995;4:189–210.
25. Penny WD, Holmes AP, Friston KJ. Random effects analysis. In: Frackowiak RS, Friston KJ, Frith CD, Dolan R, Price CJ, Zeki S, *et al.*, editors. *Human brain function*. Oxford: Oxford University Press; 2003.
26. Guenther FH, Ghosh SS, Tourville JA. Neural modeling and imaging of the cortical interactions underlying syllable production. *Brain Lang* 2006;96:280-301.
27. Petersen SE, Fox PT, Posner M, Mintun M, Raichle ME. Positron emission tomographic studies of the cortical anatomy of single-word processing. *Nature* 1988;331:585-9.
28. Vigneau M, Beaucousin V, Hervé PY, Jobard G, Petit L, Crivello F, *et al.* What is right-hemisphere contribution to phonological, lexico-semantic, and sentence processing? Insights from a meta-analysis. *Neuroimage* 2011;54:577-93.
29. Jobard G, Crivello F, Tzourio-Mazoyer N. Evaluation of the dual route theory of reading: A metanalysis of 35 neuroimaging studies. *Neuroimage* 2003;20:693-712.
30. Lee KM. Functional MRI comparison between reading ideographic and phonographic scripts of one language. *Brain Lang* 2004;91:245-51.
31. Wu CY, Ho MH, Chen SH. A meta-analysis of fMRI studies on Chinese orthographic, phonological, and semantic processing. *Neuroimage* 2012;63:381-91.
32. Kuo WJ, Yeh TC, Duann JR, Wu YT, Ho LT, Hung D, *et al.* A left-lateralized network for reading Chinese words: A 3T fMRI study. *Neuroreport* 2001;12:3997-4001.
33. Booth JR, Wood L, Lu D, Houk JC, Bitan T. The role of the basal ganglia and cerebellum in language processing. *Brain Res* 2007;1133:136-44.
34. Chen SH, Desmond JE. Cerebrocerebellar networks during articulatory rehearsal and verbal working memory tasks. *Neuroimage* 2005a; 24:332-8.
35. Rao C, Mathur A, Singh NC. 'Cost in transliteration': The neurocognitive processing of Romanized writing. *Brain Lang* 2013;124:205-12.

Cite this article as: Singh NC, Rao C. Reading in Devanagari: Insights from functional neuroimaging. *Indian J Radiol Imaging* 2014;24:44-50.

Source of Support: National Brain Research Centre, **Conflict of Interest:** None declared.